



Cross-sectional Study



PAI-1 expression in intratumoral inflammatory infiltrate contributes to lymph node metastasis in oral cancer: A cross-sectional study

Mayara Mota de Oliveira^{a,*}, Gabriela Tonini Peterle^a, Cinthia Vidal Monteiro da Silva Couto^a, Lucas de Lima Maia^a, Andre Kühl^b, Joaquim Gasparini dos Santos^a, Raquel Ajob Moysés^c, Leonardo Oliveira Trivilin^d, Aline Ribeiro Borçoi^a, Anderson Barros Archanjo^a, Arícia Leone Evangelista Monteiro de Assis^a, Fábio Daumas Nunes^e, Marcelo dos Santos^f, Adriana Madeira Álvares da Silva^a

^a Biotechnology Postgraduate Program, Federal University of Espírito Santo, Vitória, ES, Brazil

^b Department of Anatomy and Cell Biology, Wayne State University School of Medicine, Detroit, MI, USA

^c Head and Neck Surgery Service, Faculty of Medicine, University of São Paulo, São Paulo, SP, Brazil

^d Department of Veterinary Medicine, Federal University of Espírito Santo, Alegre, ES, Brazil

^e Oral and Maxillofacial Pathology Department, Faculty of Dentistry, University of São Paulo, São Paulo, SP, Brazil

^f Multicampi School of Medical Sciences, Federal University of Rio Grande do Norte, Rio Grande do Norte, Caicó, RN, Brazil

ARTICLE INFO

Keywords:

PAI-1
Oral squamous cell carcinoma
Lymph node
Prognostic marker

ABSTRACT

Introduction: Immune cells contribute with mediators in the protein expression profile of the tumor microenvironment. Levels of plasminogen activator inhibitor-1 (PAI-1) are elevated in non-malignant inflammatory conditions; however, the association between PAI-1 expression and inflammation remains uncertain in oral squamous cell carcinoma (OSCC). This study aimed to investigate PAI-1 expression in mononuclear inflammatory cell infiltrate in OSCC and its role as a prognostic marker.

Methods: Samples were collected from patients with OSCC, treated surgically, and followed for 24 months after the procedure. Thirty-nine tumoral tissue were analyzed using immunohistochemistry. Correlation between protein expression, clinicopathological parameters, and the prognosis was investigated.

Results: Positive PAI-1 expression in mononuclear inflammatory cell infiltrate was significantly associated with lymph node status ($p = 0.009$) and with the cytoplasmic expression of vascular endothelial growth factor A (VEGFA) ($p = 0.028$). Multivariate analysis revealed weak PAI-1 expression as an independent marker for lymph node metastases, with approximately 8-fold increased risk compared to strong expression (OR = 8.60; CI = 1.54–48.08; $p = 0.014$).

Conclusion: Our results suggest that the strong PAI-1 expression in intratumoral inflammatory infiltrate is an indicator of a better prognosis for patients diagnosed with oral squamous cell carcinoma.

1. Introduction

Head and neck cancer (HNC) are the seven most incident cancers in the world. In 2018, according to Global Cancer Statistics, the HNC caused 450,000 deaths [1,2]. The main risks for HNC are alcohol drinking and tobacco smoking affecting primarily men between 50 and 70 years of age [3].

Oral squamous cell carcinoma (OSCC) is the most frequent type of HNC, and yearly, it contributes 389,000 for new cases [4]. OSCC is

characterized by poor prognoses and low survival rates, with a percentual survival of about 50% in five years, and the main therapeutics procedures include surgery, radiotherapy, and chemotherapy [3]. The epidemiology disease is complex due to multifactorial and multigenic characteristics; it is linked with individual genetic susceptibility factors, lifestyle choice, and environmental agents that subjects are daily exposed [5,6].

The immune cells act as mediators of the tumor microenvironment and promote differential protein expression in tumoral tissue, resultant

* Corresponding author. Department of Biology, Biotechnology Postgraduate Program, Federal University of Espírito Santo. Address: Alto Universitário s/n, Alto Universitário, caixa postal 16, Alegre, ES, Zip code: 29500-000, Brazil.

E-mail address: mayara.oliveira@edu.ufes.br (M. Mota de Oliveira).

<https://doi.org/10.1016/j.amsu.2021.102303>

Received 24 February 2021; Received in revised form 7 April 2021; Accepted 7 April 2021

Available online 15 April 2021

2049-0801/© 2021 The Authors. Published by Elsevier Ltd on behalf of IJS Publishing Group Ltd. This is an open access article under the CC BY-NC-ND license

(<http://creativecommons.org/licenses/by-nc-nd/4.0/>).

in an inflammatory environment. The inflammation contributes to tumorigenesis through activation of protein pathways that promote angiogenesis and modify the extracellular matrix leading to metastasis and tumor progression [7,8]. In OSCC, cellular immunity presents deficits related to tumor progression, including changes in monocyte chemotaxis and defects in the interaction between antigen presenting monocytes and lymphocytes [9].

The occurrence of metastasis has a relation with fibrinolysis. The main step to this process occurs by the fibrin degradation mediated by plasmin. The fibrinolytic system is formed by urokinase cellular receptor (uPAR), urokinase (uPA), and plasminogen activator inhibitor-1 (PAI-1), and this system shows the relation with clinical aggressiveness of tumors and with the regulation of local inflammatory responses [10–12].

In the fibrinolytic system, the urokinase plasminogen activator (uPA) binds to its receptor (uPAR) and after this ligation, zymogen is converted into plasmin, which can degenerate extracellular matrix components like laminin, fibronectin, and collagen. Previous research suggests that uPA/uPAR is an important proteolytic system in cell invasion. In contrast, PAI-1 acts to inhibit the uPA/uPAR complex, which allows the binding of the low-density lipoprotein receptor-related protein 1 (LRP-1) at this complex, promoting the internalization and lysosomal degradation of uPA/PAI-1, and recycling of uPAR/LRP1 [12–14].

The metastatic process also involves the activation of several intracellular pathways. These include the vascular endothelial growth factor A (VEGFA) stands out because it promotes morphogenesis of the blood vessels, by vasculogenesis or angiogenesis. Neoangiogenesis promotes the supply of nutrients and oxygen to the tumor cells and enables the migration and establishment of these cells in other tissues [15,16].

Furthermore, PAI-1 and VEGFA are synthesized from the action of the hypoxia-inducible factor-1 transcriptional complex (HIF-1). This molecular pathway promotes the expression of genes that prevent cell death under hypoxia conditions [17].

The correlation between prognosis and PAI-1 expression in mononuclear inflammatory cell infiltrate has only recently been explored. Based on this information and on the importance of the microenvironment in tumor progression and prognosis, the present study aims to analyze the relation between PAI-1 expression in the intratumoral inflammatory infiltrate, clinicopathological features, and prognosis in oral squamous cell carcinoma.

2. Materials and methods

2.1. Ethics

This study was approved by the Medical and Health Research Committee of the Heliópolis Hospital on September 13th, 2011 (CEP n°818), São Paulo, Brazil. Written informed consent was obtained from all patients participants in this study, that followed the Declaration of Helsinki [18].

2.2. Samples

All samples from this study were collected by the Head and Neck Genome Project (GENCAPO), São Paulo, Brazil. Therefore, 39 tumoral tissue samples were used for immunohistochemical analysis of PAI-1 in mononuclear inflammatory cell infiltrate. The patients with OSCC were surgically treated at the Head and Neck Surgery Department of Heliópolis Hospital, between January 2002 and December 2008, and were followed for 24 months after surgery. The exclusions criteria used in the research were lip carcinomas, previous treatments, non-removal of cervical lymph nodes, distant metastasis, and positive surgical margins. To confirm the diagnosis and select appropriate areas for immunohistochemical analysis, histopathological slides were reviewed by a senior pathologist. All the tumors were classified following the TNM system (8th edition) [19].

2.3. Immunohistochemistry

The sections of tumor tissue with 3- μ m thick were subjected to the process of dewaxing with xylene and rehydration with graded ethanol. Then, the sections were treated with 10 mM citrate buffer solution, pH 6.0, and heated for 20 min in a microwave oven for retrieve antigenicity. After cooling off for 15 min at room temperature the endogenous peroxidase activity was blocked by incubation of slides in 3% hydrogen peroxide for 20 min. After washing in tris buffer solution, pH 7.4, tissue sections were incubated with protein blocking (Spring Bioscience) for 15 min to block non-specific staining. Then, the sections were washed with tris buffer solution and incubated with monoclonal antibodies anti-PAI1 antibody mouse 1: 100 (abcam®, Cambridge, MA, EUA, cat # 125687) and anti-VEGFA antibody mouse 1: 100 (abcam®, Cambridge, MA, EUA, cat #1316), at 4 °C overnight. The reaction was amplified with a REVEAL Polymer-HRP, mouse/rabbit (Spring Bioscience), according to the manufacturer's protocol, and was visualized with a 3,3'-diaminobenzidine as the chromogen. All sections were then counterstained with hematoxylin. Positive controls for PAI-1 (human hepatocellular carcinoma) and VEGFA (human hemangioma) and negative controls (absence of primary antibody) were used (supplementary material Fig. 1A, B, 1C, and 1D).

The semiquantitative analysis was performed following the methodology adapted from Santos et al. [20], Peterle et al. [21], Maia et al. [22] and considering the percentage of cells stained at 0 when 0% of labeled cells, 1 when 1–25% of the cells were positive; 2 when 25–50% of the cells were positive; and 3 when > 50% of the cells were positive; and by staining intensity in negative (0), weak (1), moderate (2) and strong (3). Scores received from percentage and staining intensity were multiplied and their means calculated for each sample and the resulting score was used to categorize PAI-1 in the intratumoral lymphocytic inflammatory infiltrate expression as strong (≥ 3) or weak (< 3). VEGFA cytoplasmic tumor expression and PAI-1 cytoplasmic and membrane tumor expressions were categorized as negative (0 and 1) or positive expression (> 1). All analyses were performed two different analyzers independently, and conflicting cases were re-analyzed. This study has been reported in line with the REMARK criteria [23].

2.4. Statistical analysis

Chi-square and Fisher Exact tests were used, and the values were confirmed using the Lilliefors test (significance was $p < 0.05$). Multivariate Logistic Regression was used to adjust the Odds Ratio value (OR) and the Confidence Interval (95% CI). To calculate the survival rate, the day of surgery was considered the starting point, and the endpoint was considered the date when the disease recurrence or when death occurs. For alive patients, the date of the last return appointment was used as the endpoint. The designs of the Disease-Free Survival, Local Disease-Free Survival, and Disease-Specific Survival curves were obtained using the Kaplan-Meier model and adopting the Wilcoxon p-value. Hazard Ratio (HR) and 95% CI values were adjusted using the Cox Proportional Hazards multivariate model. Statistical calculations were performed using Epi-Info® v3.4.3, 2007, and SPSS® 19.0 software.

3. Results

Among the individuals analyzed, the mean age was 68.0 ± 11.4 years, 12 (30.8%) being men, and 27 (69.2%) women. With regards to the anatomical location of tumors, 15 (38.5%) were on the tongue, 12 (30.8%) were on the floor of the mouth, 10 (25.6%) were on the gum, 2 (5.1%) were in the retromolar area. The tumor descriptions and their clinical and pathological characteristics are reported in Table 1.

PAI-1 expression in mononuclear inflammatory cell infiltrate was weak in 14 (35.9%) samples, and strong positive in 25 (64.1%) (Fig. 1A, B and C). PAI-1 expression did not show a significant association with tumor characteristics such as size ($p = 0.475$), differentiation grade ($p =$

Table 1
Epidemiological features.

Features	Cases	
	No.	(%)
Gender		
Female	27	(69.2)
Male	12	(30.8)
Age, years		
Mean (df±)	68.0 (±11.4)	
Smoking		
No	24	(61.5)
Yes	15	(38.5)
Alcohol consumption		
No	25	(64.1)
Yes	14	(35.9)
Total	39	(100.0)

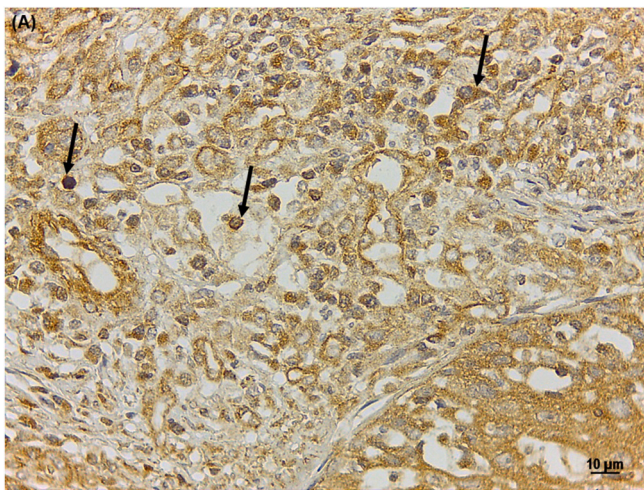


Fig. 1A. Immunohistochemistry (IHC). Strong PAI-1 in lymphoid cells of intratumoral inflammatory infiltrate. Strong positive expression. The magnification was 400×. The scale bar indicates 10 µm.

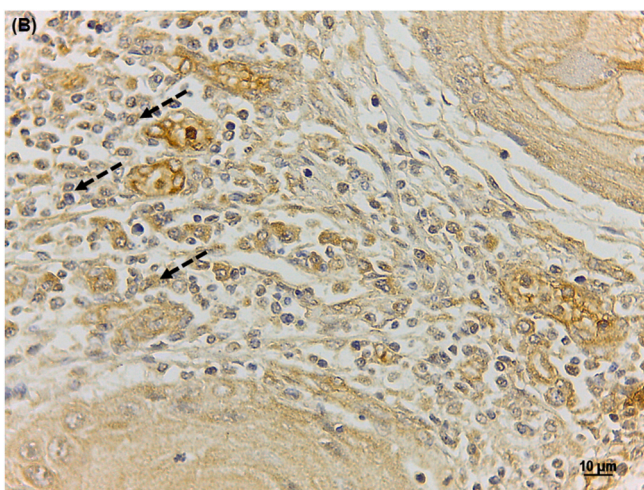


Fig. 1B. Immunohistochemistry (IHC). Weak PAI-1 in lymphoid cells of intratumoral inflammatory infiltrate. Weak positive expression. The magnification was 400×. The scale bar indicates 10 µm.

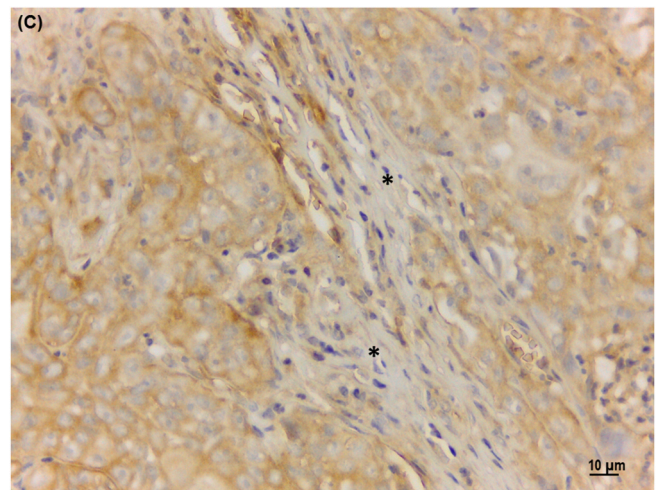


Fig. 1C. Immunohistochemistry (IHC). Negative PAI-1 in lymphoid cells of intratumoral inflammatory infiltrate. * Negative expression. The magnification was 400×. The scale bar indicates 10 µm.

0.303), lymphatic invasion ($p = 0.754$), perineural invasion ($p = 0.099$), PAI-1 cytoplasmic tumor expression ($p = 0.075$), and PAI-1 membrane tumor expression ($p = 0.281$) (Fig. 2A and B), but the expression was significantly associated with lymph node status and VEGFA cytoplasmic tumor expression ($p = 0.009$; $p = 0.028$, respectively) (Table 2). The VEGFA cytoplasmic expression in oral squamous cell carcinoma was negative in 17 (43.6%) samples and positive in 21 (53.8%) (Fig. 2C and D, Table 2).

Multivariate analysis showed that weak PAI-1 expression was an independent marker for lymph node metastases, with approximately 8-fold increased risk when compared to strong expression (OR = 8.60, CI = 1.54–48.08, $p = 0.014$, Table 3). Besides that, the lymphatic invasion also was correlated with the lymph node status (OR = 17.87, CI = 1.83–174.19, $p = 0.013$, Table 3).

Disease-Free Survival, Local Disease-Free Survival, and Disease-Specific Survival curves were obtained but p-values were not significant (data are not shown).

4. Discussion

In this research, PAI-1 expression in mononuclear inflammatory cell

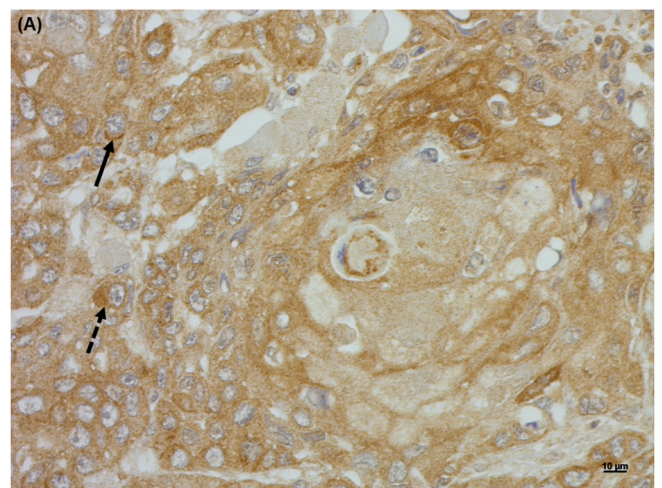


Fig. 2A. Immunohistochemistry (IHC). Positive PAI-1 membrane and cytoplasmic tumor expression. Positive membrane expression; positive cytoplasmic expression. The magnification was 400×. The scale bar indicates 10 µm.

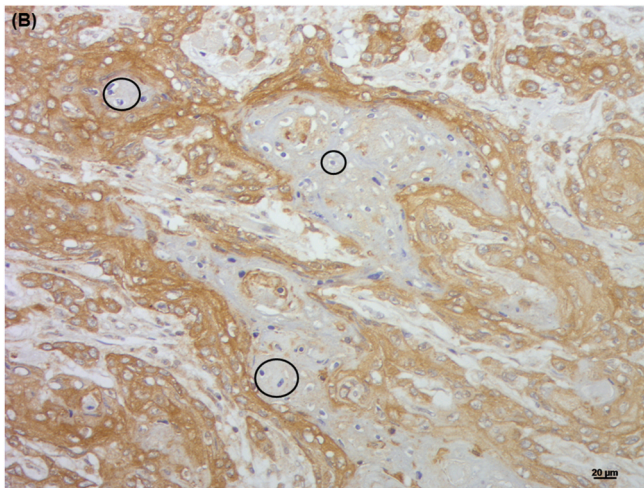


Fig. 2B. Immunohistochemistry (IHC). Negative PAI-1 membrane and cytoplasmic tumor expression. Negative membrane and cytoplasmic tumor expression. The magnification was 200 \times . The scale bar indicates 20 μ m.

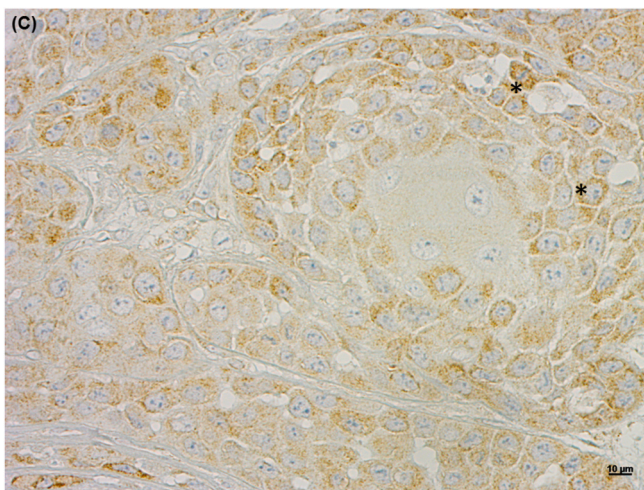


Fig. 2C. Immunohistochemistry (IHC). Positive VEGFA cytoplasmic tumor expression. * positive VEGFA expression. The magnification was 400 \times . The scale bar indicates 10 μ m.

infiltrate is a potential marker for lymph node metastases in OSCC, in which weak positive expression is associated with an approximately 8-fold increased risk. The association of PAI-1 and VEGFA also demonstrated the predictive potential of the marker in metastatic conditions.

The importance of PAI-1 in tumorigenesis is related to the role in the metastatic cascade, regulating the proliferation, migration, invasion, and adhesion of tumor cells by inhibition of uPA/uPAR complex [24, 25], in which PAI-1 participates in the clinical outcome unsatisfactory in patients with breast, ovarian, bladder and colon cancer [26].

The action of PAI-1 on inflammation is related to the activation of the hemostatic system that directs the restructuring of tissue functions after injury. In this, inflammatory mediators such as interleukin 1 (IL-1), interleukin 6 (IL-6), tumor necrosis factor- α (TNF- α) and inflammatory cytokines act on activation of fundamental mechanisms that involve antifibrinolytics release, including PAI-1, in the tissue undergoing recovery [25–30]. In this sense, low levels of PAI-1 may indicate a failure in the tissue homeostasis recovery system and may be indicative of worse prognosis.

Barajas-Castañeda et al. [31] reported that in metastatic tumors have a decrease of PAI-1 expression, suggesting a specific regulatory system

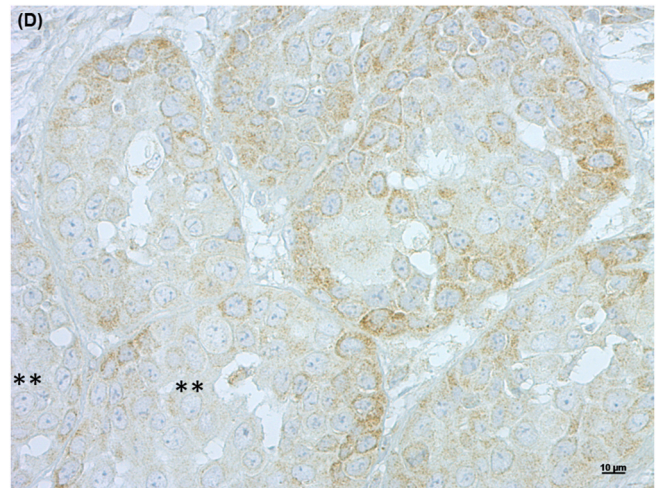


Fig. 2D. Immunohistochemistry (IHC). Negative VEGFA cytoplasmic tumor expression. **Negative VEGFA cytoplasmic tumor expression. The magnification was 400 \times . The scale bar indicates 10 μ m.

for the activation of the metastatic chain, with the involvement of the fibrinolytic pathway mediated by uPA, uPAR, and PAI-1. Another study shows the involvement of inflammatory response, neoplastic cells, and lymph nodes in the evolution of metastatic processes, these together which may indicate disease progression, worse prognosis, and decrease survival in patients diagnosed with head and neck cancer [32].

Among inflammatory responses, platelet release reaction has a relevant role and can be activated by proinflammatory and procoagulant substances, such as growth factors and PAI-1, respectively [33]. In this perspective, the positive correlation between strong PAI-1 expression in the intratumoral inflammatory infiltrate and vascular endothelial growth factor (VEGFA), shows that PAI-1 is a potential marker for a tissue homeostasis recovery system, and its expression indicates the bidirectional balancing between inflammation and homeostasis.

The finding also corroborates to the discussions about heterotypic interactions that occur in the process of tumorigenesis [34], in which the cancer cells when do not find the necessary resources for survival and development, related to the high levels of PAI-1 in the inflammatory infiltrate, starting the process of intratumoral heterogeneity and secretion of angiogenic factors to improve the nutrient and oxygen supply, and guarantee proliferation and survival [35].

The multivariate analysis also showed a positive association between the presence of lymphatic invasion and affected lymph nodes, and this can be justified by the composition of tumor microenvironment in response to inflammation, in which it is directly related to the production of angiogenic factors, proteases and growth factors, resulting in an environment that stimulates migration, proliferation and epithelial cells survival [36,37]. This hypothesis also explains the strong expression of PAI-1 in the inflammatory infiltrate found in this study: the lymphoid cells show of increase of the expression of PAI-1 as a response to start the metastatic cascade in oral squamous cell carcinoma.

Although no correlation was observed between PAI-1 in mononuclear inflammatory cell infiltrate and PAI-1 cytoplasmic and membrane tumor expressions, previous research of our group indicated the relation between tumor PAI-1 expression and invasion processes, in association with others markers of hypoxia, such as VEGFA [21]. Furthermore, in this previous research, PAI-1 proved to be a promising marker for understanding the expression of tissue factors and procoagulant induced by inflammatory stimuli.

This study strengthens research that links inflammation with worse clinical outcomes among patients, as well as corroborates the reported correlation between the expression of PAI-1 for other types of neoplasms such as breast, ovary, bladder, colon cancer and non-small cell

Table 2

Clinical and pathological features and their relation with PAI-1 expression in the mononuclear cell of the intratumoral inflammatory infiltrate.

Clinical and pathological features	PAI-1 expression						p-value
	Total		Weak		Strong		
	No.	(%)	No.	(%)	No.	(%)	
Tumor size (T)^a							
T1 + T2	19	(48.7)	8	(57.1)	11	(44.0)	0.475
T3	4	(10.3)	2	(14.3)	2	(8.0)	
T4	16	(41.0)	4	(28.6)	12	(48.0)	
Lymph node (N)^a							
Negative	22	(56.4)	4	(28.6)	18	(72.0)	0.009
Positive	17	(43.6)	10	(71.4)	7	(28.0)	
Differentiation							
Well	18	(46.2)	8	(57.1)	10	(40.0)	0.303
Moderately	21	(53.8)	6	(42.9)	15	(60.0)	
Lymphatic invasion							
Absent	29	(74.4)	10	(71.4)	19	(76.0)	0.754
Present	10	(25.6)	4	(28.6)	6	(24.0)	
Perineural invasion							
Absent	21	(53.8)	10	(71.4)	11	(44.0)	0.099
Present	18	(46.2)	4	(28.6)	14	(56.0)	
PAI-1 cytoplasmic tumor expression							
Negative	7	(17.9)	5	(35.7)	2	(8.0)	0.075
Positive	32	(82.1)	9	(64.3)	23	(92.0)	
PAI-1 membrane tumor expression							
Negative	10	(25.6)	5	(35.7)	5	(20.0)	0.281
Positive	29	(74.4)	9	(64.3)	20	(80.0)	
VEGFA cytoplasmic tumor expression							
Negative	17	(43.6)	9	(64.3)	8	(32.0)	0.028
Positive	21	(53.8)	4	(28.6)	17	(68.0)	
Not available ^b	1	(2.6)	1	(7.1)	0	(0.0)	
Disease relapse							
No	22	(56.4)	9	(64.3)	13	(52.0)	0.542
Yes	16	(41.0)	5	(35.7)	11	(44.0)	
Not available ^b	1	(2.6)	0	(0.0)	1	(4.0)	
Disease-specific death							
No	21	(53.8)	7	(50.0)	14	(56.0)	0.342
Yes	14	(35.9)	7	(50.0)	7	(28.0)	
Not available ^b	4	(10.3)	0	(0.0)	4	(16.0)	
Total	39	(100.0)	14	(35.9)	25	(64.1)	

^a TNM classification 8th edition [19].^b Not available (not considered in the statistical calculations).**Table 3**

Multivariate analysis of the relationship between lymph nodes and PAI-1 expression in the mononuclear cell of the intratumoral inflammatory infiltrate, tumor size, and lymphatic invasion.

Variables	Multivariate analysis	
	Lymphnode (N) ^a	
	OR (95% CI) ^b	p-value ^b
PAI-1 expression		
Weak	8.60 (1.54–48.08)	0.014
Strong	1	
Tumor size (T)^a		
T1	1	
T2	0.97 (0.09–10.24)	0.982
T3	1.06 (0.04–27.71)	0.974
T4	0.54 (0.04–7.10)	0.642
Lymphatic invasion		
Absent	1	
Present	17.87 (1.83–174.19)	0.013

^a TNM classification 8th edition [19].^b Values adjusted by multivariate logistic regression.

lung [38–41].

5. Conclusion

This study was able to analyze and categorize the expression of the PAI-1 in mononuclear inflammatory cell infiltrate in OSCC, in which the

high levels of PAI-1 act in the reduction of fibrinolytic activity and of metastatic evolution. Therefore, this strong PAI-1 expression is an indicator of a better prognosis in OSCC.

Funding

This work was supported by *Conselho Nacional de Desenvolvimento Científico e Tecnológico* (CNPq/133653/2012-9) and *Fundação de Amparo à Pesquisa do Estado do Espírito Santo* (FAPES/54653363/11).

Provenance and peer review

Not commissioned, externally peer reviewed.

Declaration of competing interest

The authors declare no conflict of interest.

Acknowledgments

We would like to acknowledge GENCAPO (Head and Neck Genome Project – <http://www.gencapo.famerp.br/>) for tumor samples that made the present study possible. Authors acknowledge the financial support of *Fundação de Amparo à Pesquisa do Estado do Espírito Santo* (FAPES) and research fellowships from *Conselho Nacional de Pesquisas* (CNPq) and *Coordenação de Aperfeiçoamento de Pessoal de Nível Superior* (CAPES).

Appendix A. Supplementary data

Supplementary data to this article can be found online at <https://doi.org/10.1016/j.amsu.2021.102303>.

References

- [1] F. Bray, J. Ferlay, I. Soerjomataram, R.L. Siegel, L.A. Torre, A. Jemal, A.J. Freddie Bray, Jacques Ferlay, Isabelle Soerjomataram, Rebecca L. Siegel, Lindsey A. Torre, F. Bray, J. Ferlay, I. Soerjomataram, R.L. Siegel, L.A. Torre, A. Jemal, Global cancer statistics 2018: GLOBOCAN estimates of incidence and mortality worldwide for 36 cancers in 185 countries, *CA A Cancer J. Clin.* 68 (2018) 394–424, <https://doi.org/10.3322/caac.21492>.
- [2] J. Ferlay, M. Colombet, I. Soerjomataram, C. Mathers, D.M. Parkin, M. Piñeros, A. Znaor, F. Bray, Estimating the global cancer incidence and mortality in 2018: GLOBOCAN sources and methods, *Int. J. Canc.* 144 (2019) 1941–1953, <https://doi.org/10.1002/ijc.31937>.
- [3] H.W. Hsu, N.R. Wall, C.T. Hsueh, S. Kim, R.L. Ferris, C.S. Chen, S. Mirshahidi, Combination antiangiogenic therapy and radiation in head and neck cancers, *Oral Oncol.* 50 (2014) 19–26, <https://doi.org/10.1016/j.oraloncology.2013.10.003>.
- [4] WHO. World Health Organization. International Agency for Research on Cancer, The Global Cancer Observatory: Estimated Number of Deaths from 2018 to 2040, Lip, Oral Cavity, Oropharynx and Salivary Glands - Both Sexes, All Ages, 2019. <https://who.int/gho/database/en/>. (Accessed 26 September 2020).
- [5] A. Amar, A. Rapoport, O.A. Curioni, R.A. Dedivitis, C.R. Cernea, L.G. Brandão, Prognostic value of regional metastasis in squamous cell carcinoma of the tongue and floor of mouth, *Braz J Otorhinolaryngol* 79 (2013) 734–737, <https://doi.org/10.5935/1808-8694.20130134>.
- [6] G.T. Peterle, M. Santos, S.O. Mendes, P.B. Carvalho-Neto, L.L. Maia, E. Stur, L. P. Agostini, C.V.M. Silva, L.O. Trivilin, F.D. Nunes, M.B. Carvalho, E.H. Tajara, I. D. Louro, A.M.A. Silva-Conforti, FAS ligand expression in inflammatory infiltrate lymphoid cells as a prognostic marker in oral squamous cell carcinoma, *Genet. Mol. Res.* 14 (2015) 11145–11153, <https://doi.org/10.4238/2015.September.22.8>.
- [7] M. Fanjul-Fernández, A.R. Folgueras, A. Fueyo, M. Balbín, M.F. Suárez, M. S. Fernández-García, S.D. Shapiro, J.M.P. Freije, C. López-Otín, Matrix metalloproteinase Mmp-1a is dispensable for normal growth and fertility in mice and promotes lung cancer progression by modulating inflammatory responses, *J. Biol. Chem.* 293 (2018) 11970, <https://doi.org/10.1074/jbc.AAC118.004704>.
- [8] E.G. Giacoiá, M. Miyake, A. Lawton, S. Goodison, C.J. Rosser, PAI-1 leads to G1-phase cell-cycle progression through cyclin D3/cdk4/6 upregulation, *Mol. Canc. Res.* 12 (2014) 322–334, <https://doi.org/10.1158/1541-7786.MCR-13-0543>.
- [9] V.R. Affonso, J.R.M.C. Montoro, L.C.C. Freitas, F.P. Saggiaro, L. Souza, R.C. M. Mamede, Peritumoral infiltrate in the prognosis of epidermoid carcinoma of the oral cavity, *Braz. j. otorhinolaryngol* 81 (2015) 416–421, <https://doi.org/10.1016/j.bjorl.2014.09.010>.
- [10] K. Dass, A. Ahmad, A.S. Azmi, S.H. Sarkar, F.H. Sarkar, Evolving role of uPA/uPAR system in human cancers, *Canc. Treat Rev.* 34 (2008) 122–136, <https://doi.org/10.1016/j.ctrv.2007.10.005>.
- [11] F. Pamuk, M. Lütfioğlu, A. Aydoğdu, C.Z. Koyuncuoglu, E. Cifcibasi, O.S. Badur, The effect of low-level laser therapy as an adjunct to non-surgical periodontal treatment on gingival crevicular fluid levels of transforming growth factor-beta 1, tissue plasminogen activator and plasminogen activator inhibitor 1 in smoking and non-smoking chronic periodontitis patients: a split-mouth, randomized control study, *J. Periodontol.* Res. 52 (2017) 872–882, <https://doi.org/10.1111/jre.12457>.
- [12] B.R. Binder, J. Mihaly, The plasminogen activator inhibitor "paradox" in cancer, *Immunol. Lett.* 118 (2008) 116–124, <https://doi.org/10.1016/j.imlet.2008.03.017>.
- [13] R.P. Czekay, C.E. Wilkins-Port, S.P. Higgins, J. Freytag, J.M. Overstreet, R. M Klein, C.E. Higgins, R. Samarakoon, P.J. Higgins, PAI-1: an integrator of cell signaling and migration, *Int J Cell Biol* (2011) 562481, <https://doi.org/10.1155/2011/562481>.
- [14] E.R. Kim, M.H. Yang, Y.J. Lim, J.H. Lee, D.K. Chang, Y.H. Kim, H.J. Son, J.J. Kim, J.C. Rhee, J.Y. Kimet, Association between plasma levels of plasminogen activator inhibitor-1 and colorectal neoplasms, *Gut Liver* 7 (2013) 519–523, <https://doi.org/10.5009/gnl.2013.7.5.519>.
- [15] P. Carmeliet, R.K. Jain, Molecular mechanisms and clinical applications of angiogenesis, *Nature* 473 (2011) 298–307, <https://doi.org/10.1038/nature10144>.
- [16] G.L. Semenza, Hypoxia-inducible factors in physiology and medicine, *Cell* 148 (2012) 399–408, <https://doi.org/10.1016/j.cell.2012.01.021>.
- [17] Q. Ke, M. Costa, Hypoxia-inducible factor-1 (HIF-1), *Mol. Pharmacol.* 70 (2006) 1469–1480, <https://doi.org/10.1124/mol.106.027029>.
- [18] World Medical Association declaration of Helsinki, Recommendations guiding physicians in biomedical research involving human subjects, *JAMA* 277 (1997) 925–926, <https://doi.org/10.1001/jama.1997.0354035007503>.
- [19] J.D. Brierley, M.K. Gospodarowicz, C. Wittekind, *TNM: Classification of Malignant Tumors*, Wiley: Blackwell, New Jersey, 2017.
- [20] M. Santos, A.M. Mercante, I.D. Louro, A.J. Gonçalves, M.B. Carvalho, E.H.T. Silva, A.M.A. Silva, HIF1-alpha expression predicts survival of patients with squamous cell carcinoma of the oral cavity, *PLoS One* 7 (2012), e45228, <https://doi.org/10.1371/journal.pone.0045228>.
- [21] G.T. Peterle, L.L. Maia, L.O. Trivilin, M.M. Oliveira, J.G. Santos, S.O. Mendes, E. Stur, L.P. Agostini, L.A. Rocha, R.A. Moysés, P.M. Cury, F.D. Nunes, I.D. Louro, M. Santos, A.M.A. Silva, PAI-1, CAIX, and VEGFA expressions as prognosis markers in oral squamous cell carcinoma, *J. Oral Pathol. Med.* 47 (2018) 566–574, <https://doi.org/10.1111/jop.12721>.
- [22] L.L. Maia, G.T. Peterle, M. Santos, L.O. Trivilin, S.O. Mendes, M.M. Oliveira, J. G. Santos, E. Stur, L.P. Agostini, C.V.M.S. Couto, J. Dalbó, A.L.E.M. Assis, A. B. Archanjo, A.M.C. Mercante, R.V.M. Lopez, F.D. Nunes, M.B. Carvalho, E. H. Tajara, I.D. Louro, A.M. Álvares-da-Silva, H3K9me1 Jmjd1A, H3K9me2 and ADM expression as prognostic markers in oral and oropharyngeal squamous cell carcinoma, *PLoS One* 13 (2018), e0194884, <https://doi.org/10.1371/journal.pone.0194884>.
- [23] D.G. Altman, L.M. McShane, W. Sauerbrei, S.E. Taube, Reporting recommendations for tumor marker prognostic studies (REMARK): explanation and elaboration, *PLoS Med.* 9 (2012), e1001216, <https://doi.org/10.1371/journal.pmed.1001216>.
- [24] N. Buduneli, E. Buduneli, L. Kardeşler, D. Lappin, D.F. Kinane, Plasminogen activator system in smokers and non-smokers with and without periodontal disease, *J. Clin. Periodontol.* 32 (2005) 417–424, <https://doi.org/10.1111/j.1600-051X.2005.00694.x>.
- [25] G. Pralong, T. Calandra, M.P. Glauser, J. Schellekens, J. Verhoef, F. Bachmann, E. K. Kruihof, Plasminogen activator inhibitor 1: a new prognostic marker in septic shock, *Thromb. Haemostasis* 61 (1989) 459–462, <https://doi.org/10.1055/s-0038-1646614>.
- [26] M.H. Kubala, Y.A. DeClerck, The plasminogen activator inhibitor-1 paradox in cancer: a mechanistic understanding, *Canc. Metastasis Rev.* 38 (2019) 483–492, <https://doi.org/10.1007/s10555-019-09806-4>.
- [27] E.K. Kruihof, Regulation of plasminogen activator inhibitor type 1 gene expression by inflammatory mediators and statins, *Thromb. Haemostasis* 100 (2008) 969–975, <https://doi.org/10.1160/TH08-04-0269>.
- [28] B. Van De Craen, P.J. Declerck, A. Gils, The Biochemistry, Physiology and Pathological roles of PAI-1 and the requirements for PAI-1 inhibition in vivo, *Thromb. Res.* 130 (2012) 576–585, <https://doi.org/10.1016/j.thromres.2012.06.023>.
- [29] K. Makrilakis, K. Fragiadaki, J. Smith, P.P. Sfrikakis, G.D. Kitas, Interrelated reduction of chemerin and plasminogen activator inhibitor-1 serum levels in rheumatoid arthritis after interleukin-6 receptor blockade, *Clin. Rheumatol.* 34 (2015) 419–427, <https://doi.org/10.1007/s10067-014-2704-1>.
- [30] S. Li, X. Wei, J. He, X. Tian, S. Yuan, L. Sun, Plasminogen activator inhibitor-1 in cancer research, *Biomed. Pharmacother.* 105 (2018) 83–94, <https://doi.org/10.1016/j.biopha.2018.05.119>.
- [31] L.M. Barajas-Castañeda, E. Cortés-Gutiérrez, F.M. García-Rodríguez, R. Campos-Rodríguez, E. Lara-Padilla, F. Enríquez-Rincón, M.E. Castro-Musot, P. Figueroa-Arredondo, Overexpression of MMP-3 and uPA with diminished PAI-1 related to metastasis in ductal breast cancer patients attending a public hospital in Mexico city, *J Immunol Res* (2016) 8519648, <https://doi.org/10.1155/2016/8519648>.
- [32] S.I. Grivennikov, F.R. Greten, M. Karin, Immunity, inflammation, and cancer, *Cell* 140 (2010) 883–899, <https://doi.org/10.1016/j.cell.2010.01.025>.
- [33] S. Margetic, *Inflammation and haemostasis*, *Biochem Med (Zagreb)* 22 (2012) 49–62.
- [34] D.P. Tabassum, K. Polyak, Tumorigenesis: it takes a village, *Nat. Rev. Canc.* 15 (2015) 473–483, <https://doi.org/10.1038/nrc3971>.
- [35] M. Egeblad, E.S. Nakasone, Z. Werb, Tumors as organs: complex tissues that interface with the entire organism, *Dev. Cell* 18 (2010) 884–901, <https://doi.org/10.1016/j.devcel.2010.05.012>.
- [36] J.W. Pollard, Tumour-educated macrophages promote tumour progression and metastasis, *Nat. Rev. Canc.* 4 (2004) 71–78, <https://doi.org/10.1038/nrc1256>.
- [37] D.R. Robinson, Y.M. Wu, R.J. Lonigro, P. Vats, E. Cobain, J. Everett, X. Cao, E. Rabbani, C. Kumar-Sinha, V. Raymond, S. Schuetz, A. Alva, J. Siddiqui, R. Chugh, F. Worden, M.M. Zalupski, J. Innis, R.J. Mody, S.A. Tomlins, D. Lucas, L. H. Baker, N. Ramnath, A.F. Schott, D.F. Hayes, J. Vijai, K. Offit, E.M. Stoffel, J. S. Roberts, D.C. Smith, L.P. Kunju, M. Talpaz, M. Cieślak, A.M. Chinnaiyan, Integrative clinical genomics of metastatic cancer, *Nature* 548 (2017) 297–303, <https://doi.org/10.1038/nature23306>.
- [38] S.K. Chambers, C.M. Ivins, M.L. Ivins, Plasminogen activator inhibitor-1 is an independent poor prognostic factor for survival in advanced stage epithelial ovarian cancer patients, *Int. J. Canc.* 79 (1998) 449–454.
- [39] T. Fujii, T. Obara, S. Tanno, H. Ura, Y. Kohgo, Urokinase-type plasminogen activator and plasminogen activator inhibitor-1 as a prognostic factor in human colorectal carcinomas, *Hepato-Gastroenterology* 46 (1999) 2299–2308.
- [40] N. Harbeck, M. Schmitt, C. Meisner, C. Friedel, M. Untch, M. Schmidt, C.G. J. Sweep, B.W. Lisboa, M.P. Lux, T. Beck, S. Hasmüller, M. Kiechle, F. Jänicke, C. Thomssen, Ten-year analysis of the prospective multicentre Chemo-N0 trial validates American Society of Clinical Oncology (ASCO)-recommended biomarkers uPA and PAI-1 for therapy decision making in node-negative breast cancer patients, *Eur. J. Canc.* 49 (2013) 1825–1835, <https://doi.org/10.1016/j.ejca.2013.01.007>.
- [41] M.P. Look, W.L. van Putten, M.J. Duffy, N. Harbeck, I.J. Christensen, C. Thomssen, R. Kates, F. Spyrtatos, M. Fernö, S. Eppenberger-Castori, C.G.J. Fred-Sweep, K. Ulm, J.P. Peyrat, P.M. Martin, H. Magdelenat, N. Brünner, C. Duggan, B.W. Lisboa, P. O. Bendahl, V. Quillien, A. Daver, G. Ricolleau, M.E.M. Gelder, P. Manders, W. E. Fiets, M.A. Blankenstein, P. Bröet, S. Romain, G. Daxenbichler, G. Windbichler, T. Cufer, S. Borstnar, W. Kueng, L.V.A.M. Beex, J.G.M. Klijn, N. Iggins, U. Eppenberger, F. Jänicke, M. Schmitt, J.A. Foekens, Pooled analysis of prognostic impact of urokinase-type plasminogen activator and its inhibitor PAI-1 in 8377 breast cancer patients, *J. Natl. Cancer Inst.* 94 (2002) 116–128, <https://doi.org/10.1093/jnci/94.2.116>.